

Intermittent Versus Sustained Cervical Traction in Treatment of Cervical Spondylosis

Ashraf Ramadan Hafez* and Abdul Rahim Zakaria**

*Assistant Consultant of Cairo University Hospital.

**Assistant Professor of Faculty of Applied Medical Sciences, King Saud University.

ABSTRACT

Background and purpose: Cervical spondylosis is a common degenerative condition of the cervical spine that most likely is caused by age-related changes in the intervertebral disks. Neck and shoulder pain, limited ROM, and radicular symptoms are the most common problems for these patients. Cervical traction is often used as a treatment of choice by physical therapists for treating cervical radiculopathy, however there is varying opinion about the methods of application and clinical results associated with traction. This study was conducted to evaluate differences between intermittent and sustained traction in the treatment outcome of cervical spondylosis. **Subjects and methods:** The study included forty patients divided into two groups with age ranged from 30 to 45 years (mean age 38.8 ± 6.12). The first group received physical therapy program of exercise in the form of ultrasonic therapy, stretching of cervical muscles, using deep friction massage, and intermittent cervical traction. The second group was submitted to ultrasonic therapy, stretching of cervical muscles, deep friction massage, and sustained cervical traction. For both groups there were three treatment sessions per week for 12 weeks. The cervical range of motion of side bending, and cervical extension and flexion, and pain severity on visual analogue scale was measured before and after 12 weeks of treatment. **Results:** When treatment results were compared, There was a significant difference in both groups. These differences were more significant in the first group than in the second group for ROM of cervical extension and flexion, where mean difference in flexion (4.12 ± 0.85 to 5.86 ± 0.89), in extension (5.01 ± 2.68 to 6.85 ± 1.65), and cervical side bending, where mean difference in Rt bending (62.58 ± 3.57 to 40.2 ± 1.65), in Lt bending (61.69 ± 4.01 to 43.8 ± 1.47), and cervical curve, where mean difference (9 ± 3.8 to 7 ± 3.1), but no significant difference for pain in both groups (VAS measures), mean difference (2.45 ± 0.71 to 2.58 ± 0.82). **Discussion and Conclusion:** This study showed that, intermittent traction is more effective than the sustained traction in treatment of cervical spondylosis patients.

Key words: Cervical degenerative joint disease, cervical osteoarthritis, facet joints, cervical spondylosis, cervical radiculopathy, cervical myelopathy, traction.

INTRODUCTION

The cervical spondylosis is a common degenerative condition of the cervical spine that most likely is caused by age-related changes in the intervertebral disks. Clinically, several syndromes, both overlapping and distinct, are seen: Neck and shoulder pain, suboccipital pain and headache, radicular symptoms, and cervical spondylotic myelopathy. Frequently, associated degenerative changes in the facet joints, hypertrophy of the ligamentum flavum, and ossification of the posterior longitudinal ligament occur. All can contribute to impingement on pain-sensitive structures (nerves and spinal cord), thus creating various clinical syndromes. Spondylotic changes often are observed in the aging population. However, only a small percentage of patients with radiographic evidence of cervical spondylosis are symptomatic^{1,3,12}.

Degeneration of the joint surfaces and ligaments decreases motion and can act as a limiting mechanism against further deterioration. Thickening and ossification of the posterior longitudinal ligament also decreases the diameter of the canal^{4,9,6,17,25,27}.

Pain of neck experienced with cervical spondylosis often is accompanied by stiffness, with radiation into the shoulders or occiput. It may be chronic or episodic, with long periods of remission. One third of patients with cervicgia from cervical spondylosis present with headache, and over two-thirds present with unilateral or bilateral shoulder pain. A significant amount of these patients also present with arm, forearm, and/or hand pain^{3,6,11,13}.

Common clinical syndromes associated with cervical spondylosis include the following: Chronic suboccipital headache may be present. Mechanisms include direct nerve compression; degenerative disk, joint, or ligamentous lesions; and segmental instability. Pain can be perceived locally, or it may radiate to the occiput, shoulder, scapula, or arm. The pain, which is worse when the patient is in certain positions, can interfere with sleep. Compression of the cervical nerve roots leads to ischemic changes that cause sensory dysfunction (eg, radicular pain) and/or motor dysfunction (eg, weakness). Radiculopathy most commonly occurs in those aged 40-50 years. Most cases of cervical radiculopathy resolve with conservative management; few require surgical intervention^{16,17,23}.

The cervical spine permits a wide range of motion (ROM) of the head in relation to the trunk. A degree of stability and flexibility is required to control the motion and dissipate the forces applied to the spine. Great differences in anatomy and function exist between the occiput-C1, the C1-2 (upper complex), and C3 through C7 (lower complex). Eight motion segments occur between the occiput and T1. No disc exists between C1 and C2; therefore, the first intervertebral disc is between C2 and C3^{10,14,15,21}.

X-Ray films of the cervical spine are an inexpensive way of assessing spondylotic disease in symptomatic patients. Cervical spine films can demonstrate disk space narrowing, osteophytosis, loss of cervical lordosis, uncovertebral joint hypertrophy, apophyseal joint osteoarthritis, and vertebral canal diameter. The nearly universal presence of spondylotic radiographic changes in elderly patients (and the similar appearance of a cervical spine film in a symptomatic patient and an asymptomatic patient) allows the classification of an individual patient as having mild, moderate, or severe spondylotic changes. CT is another important imaging modality. Superior to MRI in its definition of bony anatomy, CT better defines the neural foramina. CT often is used to complement MRI and provide additional bony detail to characterize a lesion responsible for neural

encroachment. Myelography also is useful for demonstrating nerve root lesions^{15,19,24}.

Cervical exercises has been advocated in patients with cervical spondylosis. Isometric exercises often are beneficial to maintain strength of the neck muscles. Neck and upper back stretching exercises, as well as light aerobic activities, also are recommended. Passive modalities generally involve the application of heat to the tissues in the cervical region, either by means of superficial devices (eg, moist-heat packs) or mechanisms for deep-heat transfer (eg, ultrasound, diathermy). Manual therapy (eg, massage, mobilization, manipulation) may provide further relief for patients with cervical spondylosis. Mobilization is performed by a physical therapist and is characterized by the application of gentle pressure within or at the limits of normal motion, with the goal of increasing the ROM. Manipulation is characterized by a high-velocity thrust, which is often delivered at or near the limit of the ROM. The intention is to increase articular mobility or realign the spine. Contraindications to manipulative therapy include myelopathy, severe degenerative changes, fracture or dislocation, infection, malignancy, ligamentous instability, and vertebrasilar insufficiency^{6, 9,12, 18,22,23}.

Traction can be applied manually or by use of motorized units. Motorized traction can be applied intermittently or in a continuous manner. Cervical traction is often used as a treatment of choice by physical therapists for treating cervical radiculopathy, however there is varying opinion about the methods of application and clinical results associated with traction^{20,24}. Speculated effects of traction include the following:

1. Unloading of the components of the spine by stretching muscles, ligaments and functional units. The stretching results in distraction of articular surfaces.
2. Prevention and lysis of adhesions within the dural sleeve.
3. Relief of nerve root compression within the central foramina.
4. Decreased pressure within the intervertebral discs.
5. Relief of tonic muscle contraction.

6. Improved vascular status within the epidural space and perineural structures.²⁴

The aim of the current study is to compare between intermittent and sustained traction in treatment of cervical spondylosis.

MATERIALS AND METHODS

Subjects

The study included forty patients divided into two groups with age ranged from 30 to 45 years (mean age 38.8 ± 6.12). The first group (12 female and 8 male) received physical therapy program of exercise in the form of ultrasonic therapy, stretching of cervical muscles, deep friction massage, and intermittent cervical traction. The second group (11 female and 9 male) was submitted to ultrasonic therapy, stretching of cervical muscles, deep friction massage, and sustained cervical traction. For both groups there were three sessions per week for 12 weeks. All the patients were listed at our clinic of orthopaedic departments at Cairo University hospitals. All of them were suffering from neck pain, radicular pain and limitation of ROM of cervical movement.

Instrumentations

- 1- Visual analogue scale to measure the pain severity (VAS).
- 2- Tape measurement to detect range of motion of cervical extension and flexion.
- 3- Universal goniometer to measure ROM of side bending.
- 4- Loading x-ray (Siemens Poly phase 50 apparatus, Siemens).

Procedures

The patients signed an informed consent form, and were informed about the whole procedures before testing and training:

Treatment procedures:

The first group followed a physical therapy program of exercise in the form of Ultrasonic therapy (3 minutes, 1.5 w/sec^2 in continuous mode), stretching of cervical muscles in directions of side bending and rotation (5 repetitions, 30 seconds in position of stretching, 30 seconds in position of relaxation), with using deep friction massage 5 minutes at the site of cervical region, and

intermittent cervical traction, from sitting position through electric traction adjusted as 30 seconds in position of traction, 30 seconds in position of relaxation, for 10 minutes, using the head position that most effectively reduces or relieves the symptoms, three sessions per week for 12 weeks.

The second group, submitted to the physical therapy program of Ultrasonic therapy (3 minutes, 1.5 w/sec^2 in continuous mode), stretching of cervical muscles in directions of side bending and rotation (5 repetitions, 30 seconds in position of stretching, 30 seconds in position of relaxation), deep friction massage is also used for 5 minutes at the site of cervical region, and sustained cervical traction from sitting position through electric traction adjusted as sustained traction, for 10 minutes², using the head position that most effectively reduces or relieves the symptoms, three sessions per week for 12 weeks.

Assessment procedures:

All the patients were assessed before treatment and reassessed after 12 weeks by:

- 1- Visual analogue scale to measure the pain which is represented from (0) grade to (10) grade. Zero grade means no pain, (10) grade means unbearable pain, from 1 to 10 means graduation intensities of pain. The subjects were asked to indicate the level of pain by placing a dash at the appropriate level on the 10 cm horizontal line.
- 2- Tape measurement to detect range of motion of cervical extension and flexion. From the center of chin to the xiphoid process in flexion, and the center of occiput to the seventh cervical in extension, in the midposition and at the end of flexion and extension.
- 3- Universal goniometer, to measure ROM of side bending, the fixed arm of the goniometer is placed in parallel to the level of the shoulder and the movable arm in parallel to the in 90° position then the subject were asked to side bend to left and right and record the angle of left and right side bending.
- 4- Lateral view of x-ray is to detect any change in lordotic curve of cervical region (by meeting of two lines, a

horizontal line from the superior surface of the first cervical vertebra and a horizontal line from the superior surface of seven cervical vertebra).

Data Analysis

The collected data were statistically treated and the following values were found minimum, maximum, mean, S.D., one sample paired T-test to compare between pre and post in the group and two sample unpaired t-test to compare between 2 groups, at a confidence level of (P = 0.05).

RESULTS

The results of the first group: There was a significant improvement of pain after physical therapy treatment from VAS value (6.91±1.36) to (2.45±0.71), ROM of neck flexion increased from (7.23±1.87) to (4.12±0.85), ROM of neck extension increased from (9.53±4.23) to (5.01±2.68), Rt.neck side bending increased from (32.54±2.25) to (62.58±3.57), Lt.neck side bending increased from (40.35±2.89) to (61.69±4.01), and cervical curve increased from (6.5±2.63) to (9±3.8) tab. (1) fig. (1).

Table(1): pre and post values of pain, ROM of neck flexion, ROM of neck extension, Rt.neck side bending, Lt.neck side bending, and cervical curve in first group.

	Pain		neck flexion		neck extension		Rt.neck side bending		Lt.neck side bending		cervical curve	
	Pre	Post	Pre	Post	Pre	Post	Pre	Post	Pre	Post	Pre	Post
Min	3	1	6	3	7	4	25	50	30	53	5	8
Max	8	4	9	5.5	11	6	45	70	48	72	8	10
Mean	6.91	2.45	7.23	4.12	9.53	5.01	32.54	62.58	40.35	61.69	6.5	9
SD	1.36	0.71	1.87	0.85	4.23	2.68	2.25	3.57	2.89	4.01	2.63	3.8
t-test	0.003*		0.008*		0.004*		0.009*		0.005*		0.03*	

(*) significant, P ≤ 0.05

(**) no significant, P ≥ 0.05

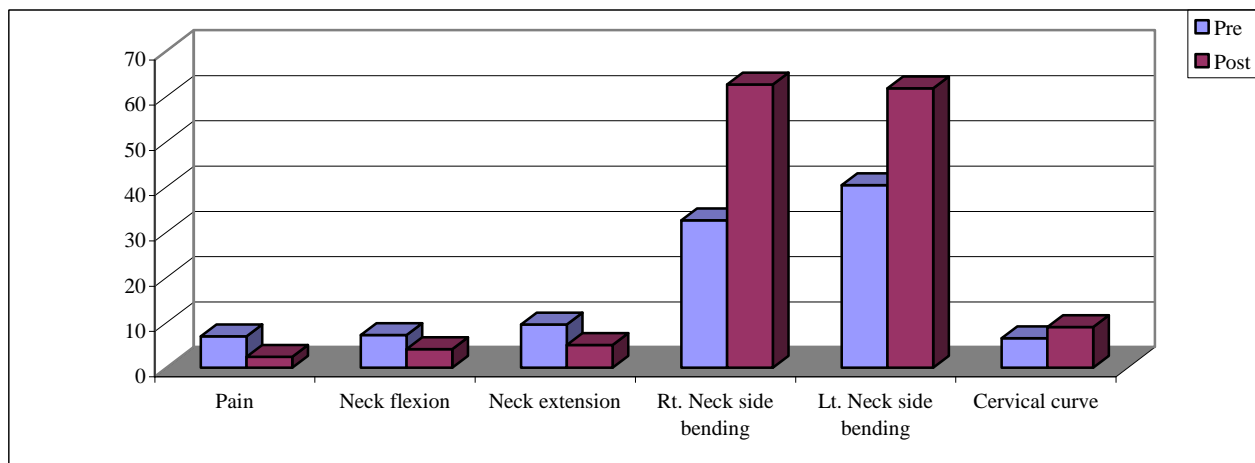


Fig. (1): The mean values of pain, ROM of neck flexion, ROM of neck extension, Rt.neck side bending, Lt.neck side bending, and cervical curve in first group.

The results of the second group: There was a significant improvement of pain after physical therapy treatment from (6.54±1.47) to (2.58±0.82), ROM of neck flexion increased from (7.45±1.64) to (5.86±0.98), ROM of neck extension increased from (8.95±2.87) to

(6.85±1.65), Rt.neck side bending increased from (33.36±2.46) to (40.2±1.63), Lt.neck side bending increased from (38.65±2.34) to (43.8±1.47), and cervical curve increased from (5.5±2.26) to (7±3.1) tab.(2) fig.(2).

Table(2): pre and post values of pain, ROM of neck flexion, ROM of neck extension, Rt.neck side bending, Lt.neck side bending, and cervical curve in first group.

	Pain		neck flexion		neck extension		Rt.neck side bending		Lt.neck side bending		cervical curve	
	Pre	Post	Pre	Post	Pre	Post	Pre	Post	Pre	Post	Pre	Post
Min	4	2	7	5	7	5	26	33	31	37	4	6
Max	9	4	9	7	10	7	48	55	46	54	7	8
Mean	6.54	2.58	7.45	5.86	8.95	6.85	33.36	40.2	38.65	43.8	5.5	7
SD	1.47	0.82	1.64	0.98	2.87	1.65	2.46	1.63	2.34	1.47	2.26	3.1
t-test	0.006*		0.01*		0.02*		0.02*		0.01*		0.04*	

(*) significant, $P \leq 0.05$

(**) no significant, $P \geq 0.05$

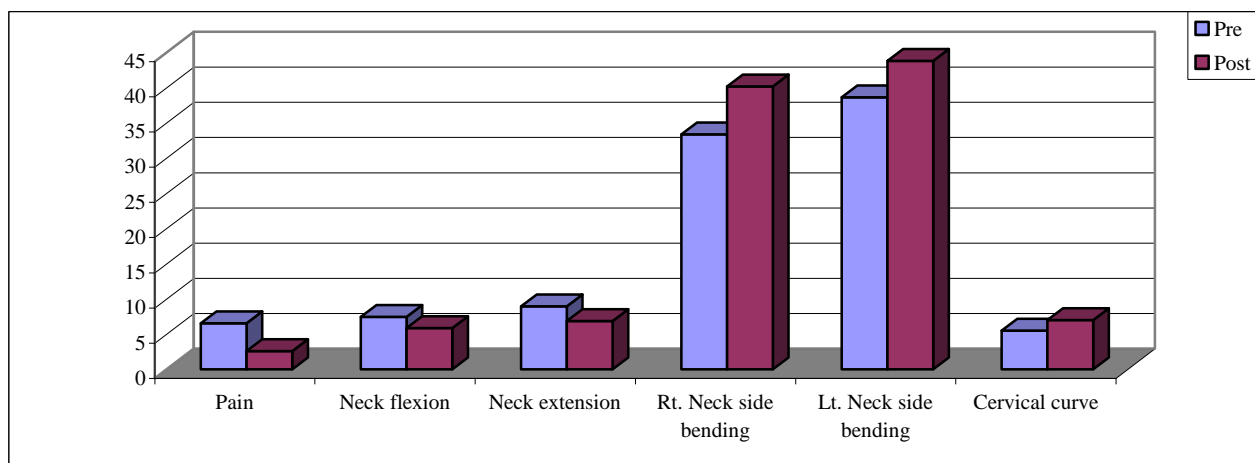


Fig. (2): The mean values of pain, ROM of neck flexion, ROM of neck extension, Rt.neck side bending, Lt.neck side bending, and cervical curve in first group.

Comparison between both groups

When treatment results were compared, There was a significant difference in both groups. These differences were more significant in the first group than in the second group for ROM of cervical extension and flexion, where mean difference in flexion (4.12 ± 0.85 to 5.86 ± 0.89), in extension

(5.01 ± 2.68 to 6.85 ± 1.65), and cervical side bending, where mean difference in Rt bending, where mean difference in Rt bending (62.58 ± 3.57 to 40.2 ± 1.65), in Lt bending (61.69 ± 4.01 to 43.8 ± 1.47), and cervical curve, where mean difference (9 ± 3.8 to 7 ± 3.1), but no significant difference for pain in both groups (VAS measures), mean difference (2.45 ± 0.71 to 2.58 ± 0.82) tab.(3) fig. (3).

Table (3): The mean values of post test of pain, ROM of neck flexion, ROM of neck extension, Rt. neck side bending, and Lt.neck side bending, and cervical curve in both groups.

	Pain		neck flexion		neck extension		Rt.neck side bending		Lt.neck side bending		cervical curve	
	1st gr.	2nd gr.	1st gr.	2nd gr.	1st gr.	2nd gr.	1st gr.	2nd gr.	1st gr.	2nd gr.	1st gr.	2nd gr.
Min	1	2	3	5	4	5	50	33	53	37	8	6
Max	4	4	5.5	7	6	7	70	55	72	54	10	8
Mean	2.45	2.58	4.12	5.86	5.01	6.85	62.58	40.2	61.69	43.8	9	7
SD	0.71	0.82	0.85	0.98	2.68	1.65	3.57	1.65	4.01	1.47	3.8	3.1
t-test	0.65**		0.045*		0.04*		0.03*		0.02*		0.05*	

(*) significant, $P \leq 0.05$

(**) no significant, $P \geq 0.05$

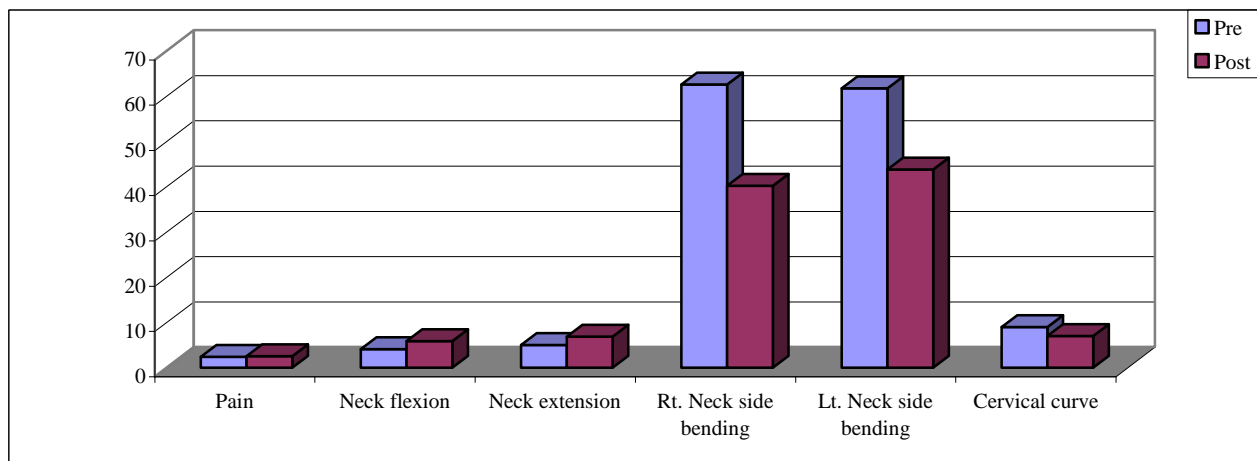


Fig. (3): The mean values of post test of pain, ROM of neck flexion, ROM of neck extension, Rt. neck side bending, and Lt. neck side bending, and cervical curve in both groups.

DISCUSSION

The results of this study showed that there was a significant improvement of pain, and ROM of neck flexion, neck extension, Rt. neck side bending, and Lt. neck side bending and cervical curve in first group due to using of exercise program which include: ultrasonic therapy can relax the tense soft-tissues through its micromassage effect, stretching exercise which decreasing spasm of the muscles and improve the circulation which decrease the concentration of metabolites^{7,8}.

Strengthening and stretching weakened or strained muscles is usually the first treatment that is advised. Your physical therapist may also use cervical (neck) traction and posture therapy. Physical therapy programs vary, but they generally last from 6 to 12 weeks. Sessions are scheduled 2 to 3 times a week^{8,26}.

Deep friction massage which produces therapeutic movement by breaking down the strong cross links or adhesions that have been formed, softening the scar tissue and mobilising the cross links between the mutual collagen fibres and the adhesions between repairing connective tissue and surrounding tissues, and also modulates of the nociceptive impulses at the level of the spinal cord: the "gate control theory". The centripetal projection into the dorsal horn of the spinal cord from the nociceptive receptor system is inhibited by the concurrent activity of the mechanoreceptors located in the same tissues, leads to increased destruction of pain

provoking metabolites, such as Lewis's substances. This metabolite, if present in too high a concentration, causes ischaemia and pain^{5,7,8,26}.

Traction techniques can be used for the purposes of stretching the muscles and the facet joint capsules and widening the intervertebral foramina. The value of traction is that the angle of pull, head position, and placement of the force can be controlled²⁰.

Intermittent traction is effective in relieving pain, increasing the frequency of myoelectric signals, improving blood flow in affected muscles, and improving the imbibition sign of disc nutrition through distraction and compression²⁴. And also used to reduce radicular symptoms by decreasing foraminal compression and intradiscal pressures^{2,20}.

The improvement of ROM of neck flexion and extension occurs consequently to pain reduction which is responsible for the improvement in muscle function. The results of this study come in agreement with many previous findings. There was a significant improvement of pain, and ROM of neck flexion, neck extension, Rt. neck side bending, and Lt. neck side bending and cervical curve in second group due to using of exercise program which include: ultrasonic therapy can relax the tense soft-tissues through its micromassage effect, stretching exercise, deep friction massage), traction was used to promotes immobilization of the cervical region and widens the foraminal openings. Both of intermittent and sustained traction are sharing in cervical joint distraction which may loosen

adhesions within the dural sleeves, reduce compression and irritation of disks, and improve circulation within the epidural space^{7,8,26}.

In comparison of results of both groups, there is no significant improvement of pain, but there is significant improvement of ROM of neck flexion and neck extension, Rt. neck side bending, and Lt. neck side bending and cervical curve in first group which using intermittent traction than in the second group which using sustained traction because of intermittent traction may be better tolerated than sustained traction in some patients, with intermittent traction probably more effective than static traction²⁰.

The results of the current study showed the effect of intermittent traction during treatment of cervical spondylosis. We found that the improvement in the first group was significant more than in the second group in improvement of ROM of neck flexion, extension, Rt. neck side bending, and Lt. neck side bending and cervical curve. From all of the above, we found that the using of intermittent traction is very effective during treatment of cervical spondylosis patients.

Conclusion: This study showed that, intermittent traction is very important to be included in the program of treatment of cervical spondylosis patients.

REFERENCES

- 1- Ahlgren, B.D. and Garfin, S.R.: Cervical Radiculopathy, *Orthop Clin North Am*, Apr; 27(2): 253-263, 1996.
- 2- Akinbo, S.R., Noronha, C.C., Okanlawon, A.O. and Danesi, M.A.: Effects of different cervical traction weights on neck pain and mobility, *Niger Postgrad Med J. Sep*;13(3): 230-235, 2006.
- 3- Alexander, J.T.: Natural history and nonoperative management of cervical spondylosis. In: Menezes AH, Sonntag VKH, *Principles of Spinal Surgery*, 1: 547-557, 1996.
- 4- Boyce, R.H. and Wang, J.C.: Evaluation of neck pain, radiculopathy and myelopathy: imaging, conservative treatment, and surgical indications; 52: 489-495, 2003.
- 5- Chamberlain, G.: Cyriax's friction massage: a review. *J Orthop Sports Phys Ther*, 4: 16-22, 1982.
- 6- Chesnut, R.M., Abitbol, J.J. and Garfin, S.R.: Surgical management of cervical radiculopathy. Indication, techniques, and results, *Orthop Clin North Am*, Jul; 23(3): 461-474, 1992.
- 7- Goats, G.C.: Massage: the scientific basis of an ancient art. Part 2. Physiological and therapeutic effects. *Br J Sports Med*; 28: 153-156, 1994.
- 8- Gregory, M., Deane, M. and Mars, M.: Ultrastructural changes in untraumatized rabbit skeletal muscle treated with deep transverse friction. *Physiotherapy*; 89: 408, 2003.
- 9- Denno, J.J. and Meadows, G.R.: Early diagnosis of cervical spondylotic myelopathy. A useful clinical sign, *Spine*, Dec; 16(12): 1353-1355, 1991.
- 10- Ellenberg, M.R., Honet, J.C. and Treanor, W.J.: Cervical radiculopathy, *Arch Phys Med Rehabil*, Mar; 75(3): 342-352, 1994.
- 11- Emery, S.E.: Cervical spondylotic myelopathy: diagnosis and treatment, *J Am Acad Orthop Surg*, Nov-Dec; 9(6): 376-388, 2001.
- 12- Fouyas, I.P. and Statham, P.F.: Operative treatment of cervical spondylosis, *Br J Neurosurg*, Dec; 12(6): 594-595, 1998.
- 13- Heller, J.G.: The syndromes of degenerative cervical disease, *Orthop Clin North Am*, Jul; 23(3): 381-394, 1992.
- 14- Iwabuchi, M., Kikuchi, S. and Sato, K.: Pathoanatomic investigation of cervical spondylotic myelopathy, *Fukushima J Med Sci*, Dec; 50(2): 47-54, 2004.
- 15- Kadanka, Z., Mares, M. and Bednanik, J.: Approaches to spondylotic cervical myelopathy: conservative versus surgical results in a 3-year follow-up study, *Spine*, Oct 15; 27(20): 2205-2210, 2002.
- 16- Kadanka, Z., Mares, M. and Bednarik, J.: Predictive factors for spondylotic cervical myelopathy treated conservatively or surgically. *Eur J Neurol*, Jan; 12(1): 55-63, 2005.
- 17- Kramer, J., Rivera, C.A. and Kleefeld, J.: Degenerative disorders of the cervical spine, *Rheum Dis Clin North Am*, Aug; 17(3): 741-755, 1991.
- 18- Malanga, G.A.: The diagnosis and treatment of cervical radiculopathy, *Med Sci Sports Exerc*, Jul; 29 (7 Suppl): S236-451997, 1997.
- 19- McCormick, W.E., Steinmetz, M.P. and Benzel, E.C.: Cervical spondylotic myelopathy: make the difficult diagnosis, then refer for surgery, *Cleve Clin J Med*; 70(10): 899-904, 2003.
- 20- Nippon Ika Daigaku Zasshi: [Effects of intermittent cervical traction on muscle pain.

- and electromyographic studies of the cervical paraspinal muscles, Apr; 61(2): 137-147, 1994.
- 21- Ordway, N.R., Seymour, R.J. and Donelson, R.G.: Cervical flexion, extension, protrusion, and retraction. A radiographic segmental analysis, Spine, Feb 1; 24(3): 240-247, 1999.
- 22- Papadopoulos, S.M. and Hoff, J.T.: Anatomical treatment of cervical spondylosis, Clin Neurosurg; 41: 270-285, 1994.
- 23- Sari-Kouzel, H. and Cooper, R.: Managing pain from cervical spondylosis, Apr; 243(1597): 334-338, 1999.
- 24- Swezey, R.L., Swezey, A.M. and Warner, K.: Efficacy of home cervical traction therapy, Am J Phys Med Rehabil, Jan-Feb; 78(1): 30-32, 1999.
- 25- Tsiptsios, I., Fotiou, F., Sitzoglou, K. and Fountoulakis, K.N.: Neurophysiological investigation of cervical spondylosis. Electromyogr Clin Neurophysiol, Jul-Aug; 41(5): 305-313, 2001.
- 26- Walker, H.: Deep transverse frictions in ligament healing. J Orthop Sports Phys Ther; 6: 89-94, 1984.
- 27- Wilkinson, M.: The morbid anatomy of cervical spondylosis and myelopathy. Brain, Dec; 83: 589-617, 1960.

المخلص العربي

شد الفقرات العنقية المتقطع مقابل المضرب في علاج خشونة الفقرات العنقية

الهدف من هذه الدراسة تقييم مدى تأثير برنامج العلاج الطبيعي المتمثلين في عمل شد رقبة متقطع وشد رقبة مستمر في حالات الخشونة الموجودة بالمنطقة العنقية وهي من أهم أسباب آلام الرقبة والكتفين وأيضا إعاقة لبعض الأنشطة اليومية . تشمل الدراسة أربعون مريضا من الذكور والإناث تتراوح أعمارهم من ثلاثون إلى خمسة وأربعون سنة . بعد أن تم تشخيص المرضى إكلينيكيًا ، تم تقسيم المرضى عشوائيًا إلى مجموعتين متساويتان في العدد : المجموعة الأولى عشرون مريضًا خضعت لبرنامج العلاج الطبيعي المتمثل في عمل موجات صوتية وشد رقبة متقطع مع استخدام تمرينات لشد عضلات الرقبة ، وتدليك عميق لنفس العضلات لمدة ستة أسابيع ثلاث مرات أسبوعيا . المجموعة الثانية عشرون مريضًا خضعت لبرنامج العلاج الطبيعي المتمثل في عمل موجات صوتية وشد رقبة مستمر مع استخدام تمرينات لشد عضلات الرقبة، وتدليك عميق لنفس العضلات لمدة ستة أسابيع ثلاث مرات أسبوعيا ، نفس البرنامج بنفس الأخصائي لكل المرضى . تم تقييم الألم بالمدرج البصري للألم والمدى الحركي للرقبة بمقياس المدى الحركي للمفصل ومقياس بالسننيمتر وانحناء الفقرات القطنية بـشعة اكس . وقد بينت النتائج الإحصائية وجود تحسن ملحوظ في الألم والمدى الحركي في المجموعتين ولكن هناك تحسن أكثر في المجموعة الأولى عن المجموعة الثانية ووجود فوارق ذات دلالة إحصائية بينهما . وقد ظهر من الدراسة أن برنامج العلاج الطبيعي الأول أكثر تأثيرا لعلاج مرضى حالات الخشونة الموجودة بالمنطقة العنقية. ولذا يقترح أهمية الشد المتقطع في علاج هذه الحالات .