

# **TESTING OF FASCIAL MUSCLES**

**Yasser Moh. Aneis, PhD, MSc., PT.**

**Lecturer of Physical Therapy**

**Basic Sciences Department**



**Tests & Measurements**



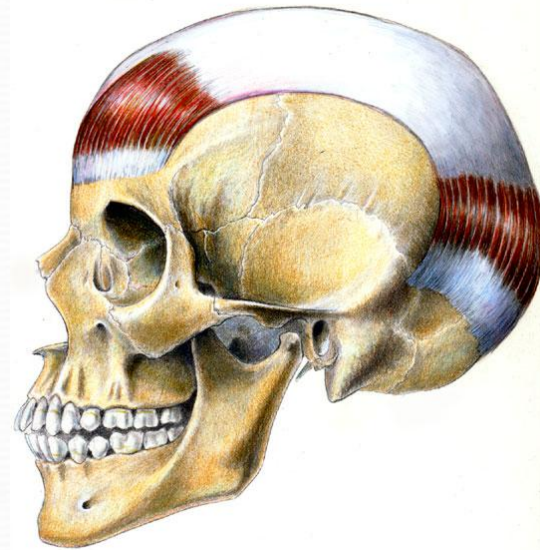# **TESTING OF FASCIAL MUSCLES**

# FASCIAL MUSCLES

- Muscles of the face
- Muscles of the eye
- Muscles of the mouth
- Muscles of mastication

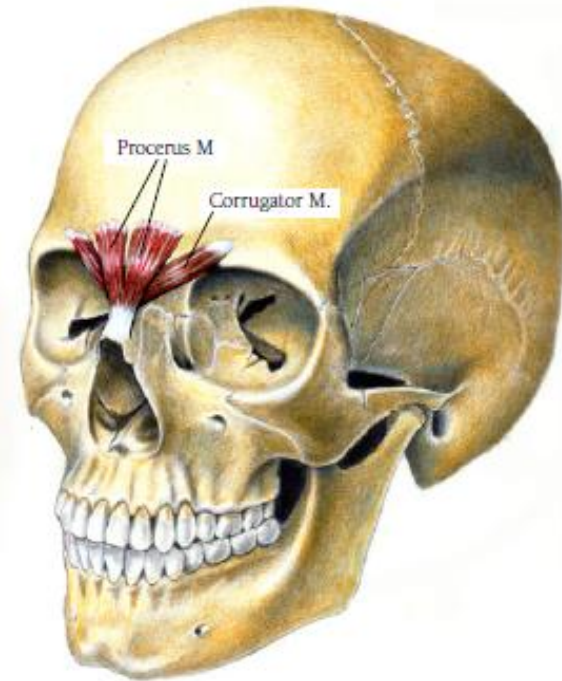
# MUSCLES OF THE FACE

## ○ Frontalis Muscle



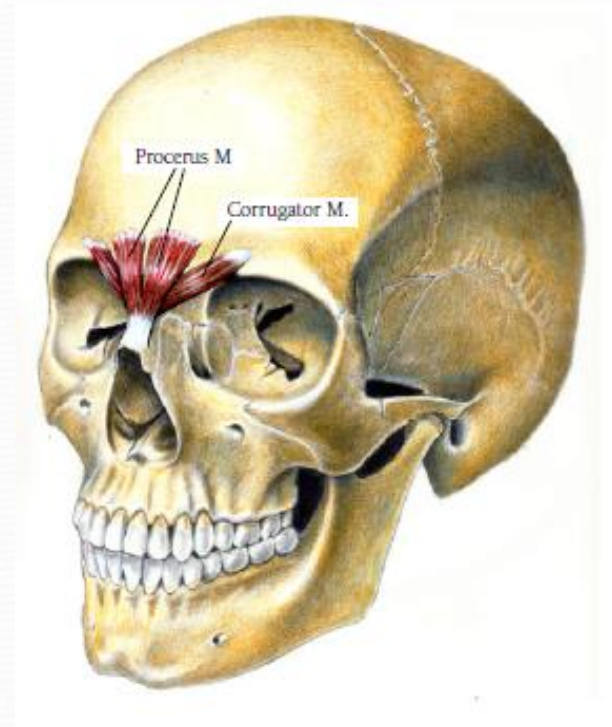

***Test:*** Raise the eyebrows, wrinkling the forehead, as in an expression of surprise or fright.

# ○Corrugator Muscle



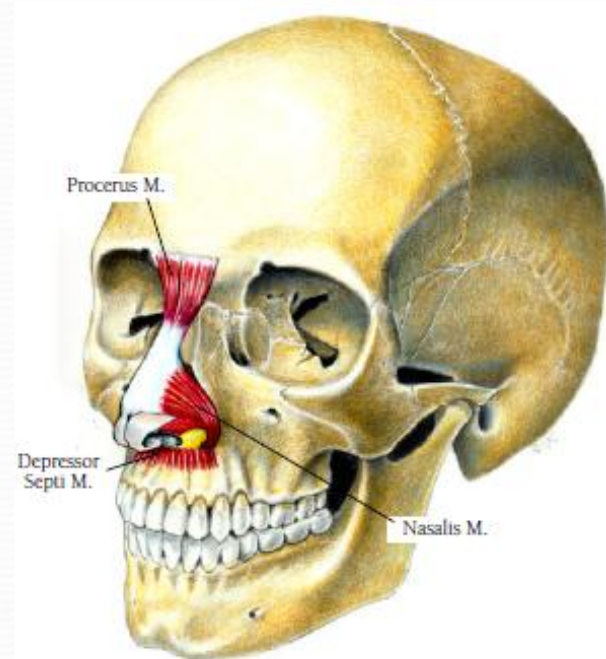
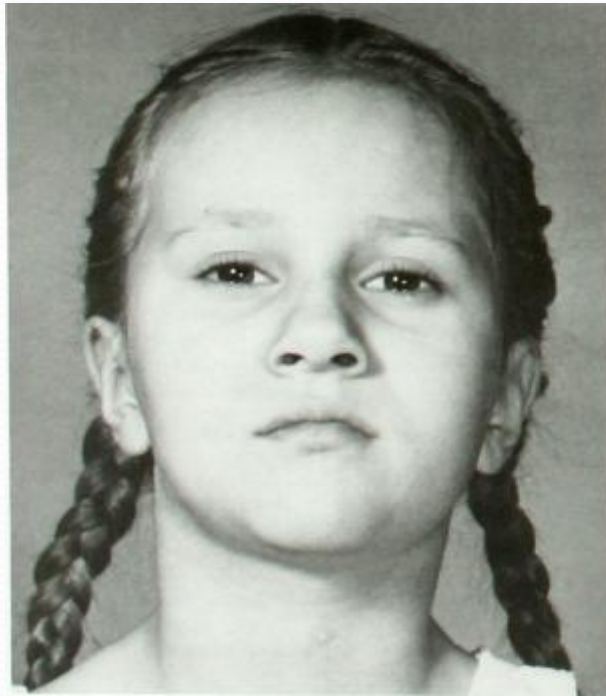***Test:*** Draw the eyebrows together, as in frowning.

## ○ Procerus Muscle



***Test:*** Pull the skin of the nose upward, forming transverse wrinkles over the bridge of the nose.

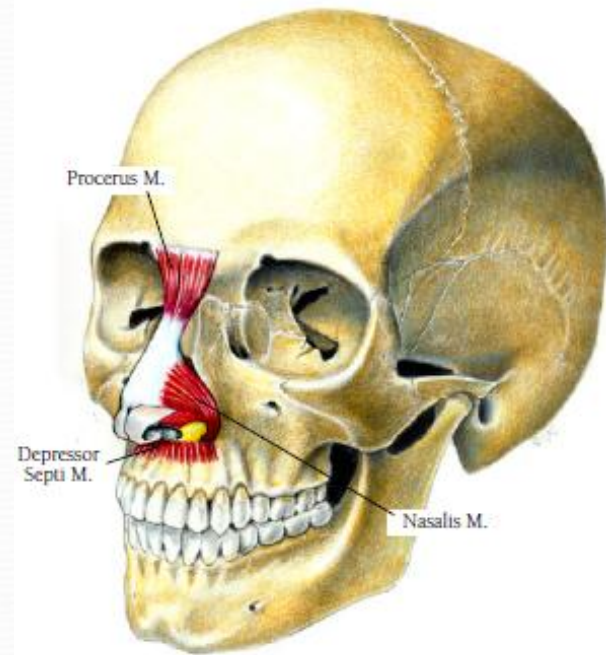
## ○Nasalis Muscle (alar portion)



***Test:*** Widen the apertures of the nostrils, as in forced or difficult breathing.



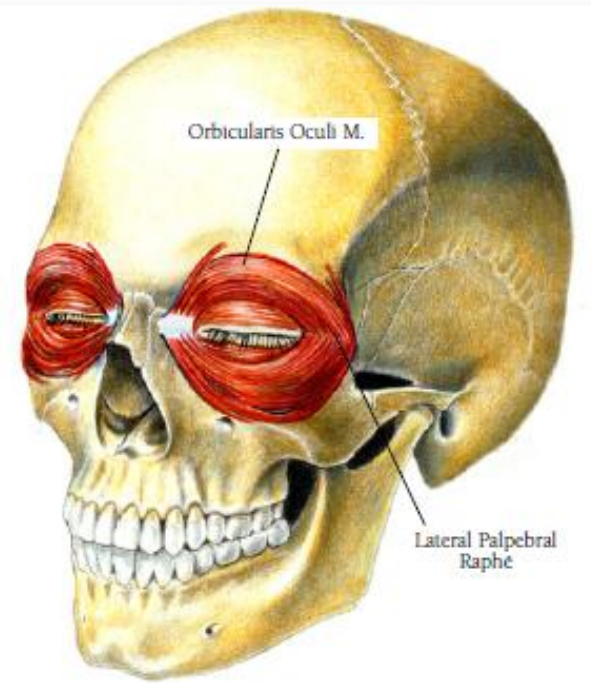
## ○Nasalis Muscle (Transverse Portion)



***Test:*** Draw the point of the nose downward, narrowing the nostrils.

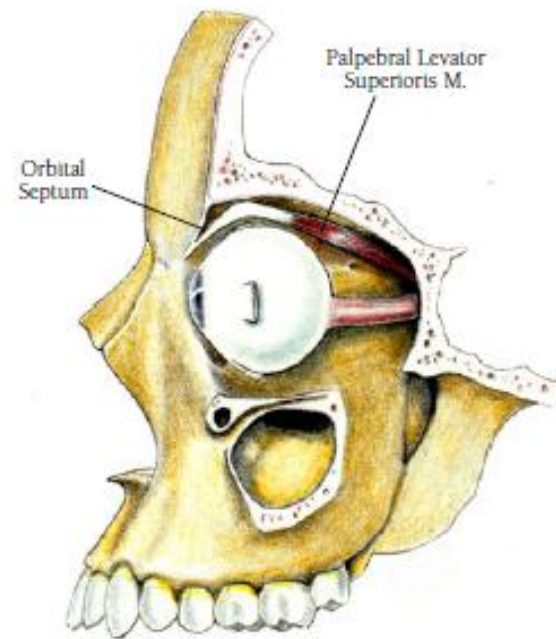
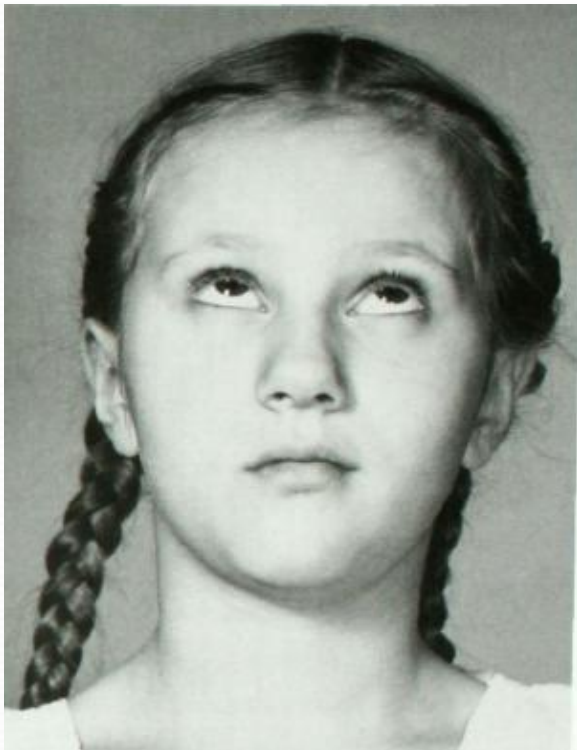# MUSCLES OF THE EYE

## ○Orbicularis Oculi Muscle



**Test, orbital Part:** Close the eyelid firmly forming wrinkles that radiate from outer angle. **Palpebral Part:** Close the eyelid gently.

# Levator Palpebrae Superioris Muscle



***Test:*** Levator Palpebrae Superioris: Raise the upper eyelid.

# ○ Rectus Medialis Oculi and Rectus Lateralis Oculi Muscles

- ***Test, Right Rectus Medialis and Left Rectus Lateralis:***

Look horizontally toward the left.

- ***Test, Left Rectus Medialis and Right Rectus Lateralis:***

Look horizontally toward the right.

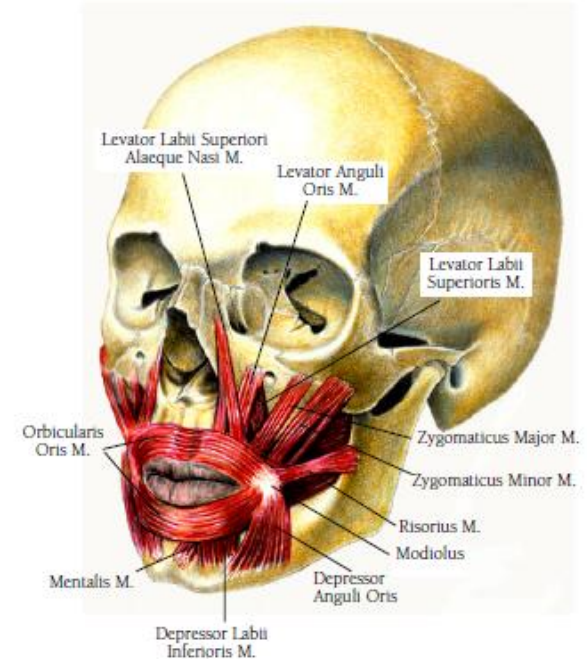
RECTUS MEDIALIS OCULI AND  
RECTUS LATERALIS OCULI



*Right Rectus Medialis and Left Rectus Lateralis*

# MUSCLES OF THE MOUTH

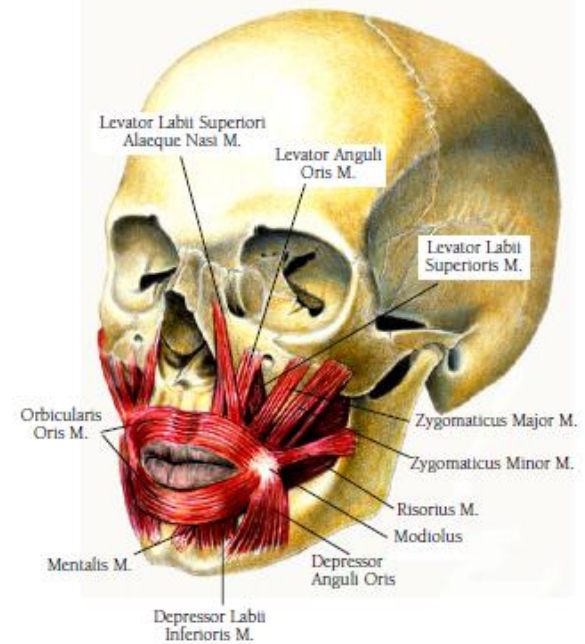
## ○Risorius Muscle



***Test:*** Draw the angle of the mouth backward.

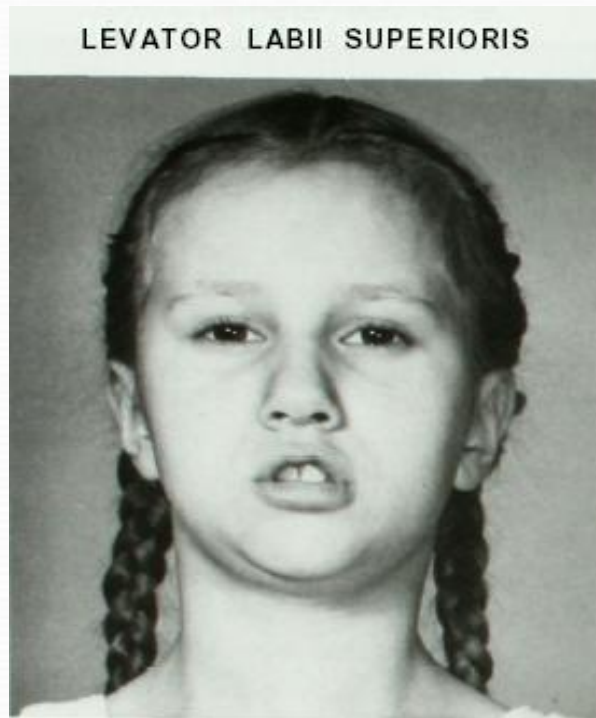# Zygomaticus Major Muscle

ZYGOMATICUS MAJOR

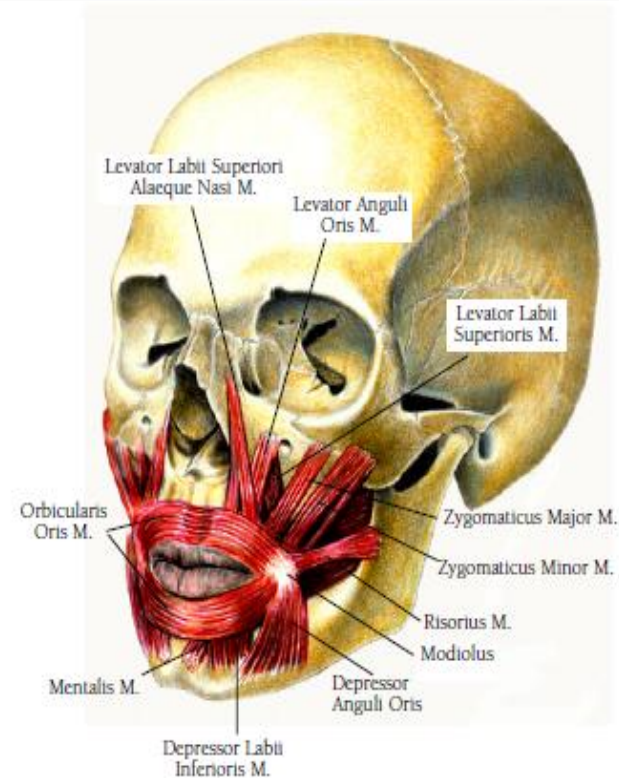


***Test:*** Draw the angle of the mouth upward and outward, as in smiling.

# Levator Labii Superioris Muscle



Test: Raise and protrude the upper lip, as if to show the upper gums.



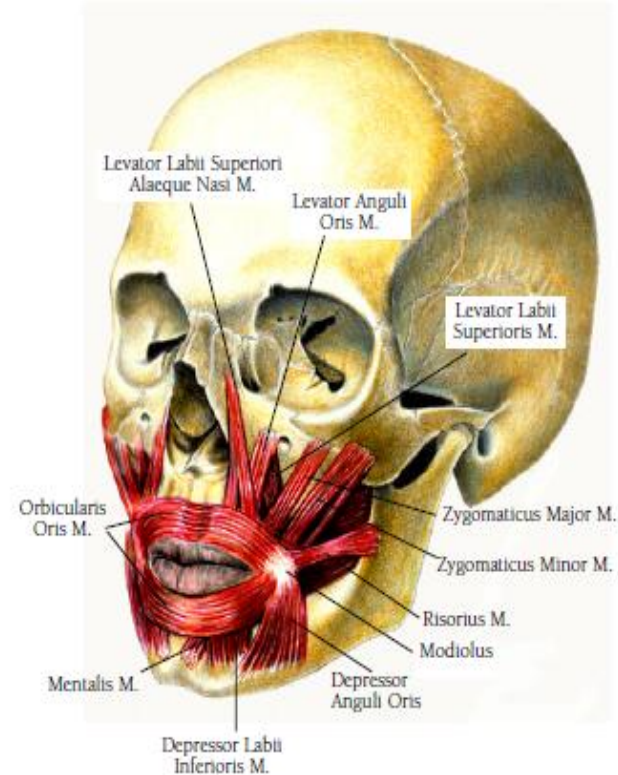
***Test:*** Raise and protrude the upper lip, as if to show the upper gums.

# ○ Depressor Labii Inferioris and Platysma Muscles

DEPRESSOR LABII INFERIORIS  
AND PLATYSMA



Test: Draw the lower lip and angle of the mouth downward and outward, tensing the skin over the neck.



***Test:*** Draw the lower lip and angle of the mouth downward and outward, tensing the skin over the neck.

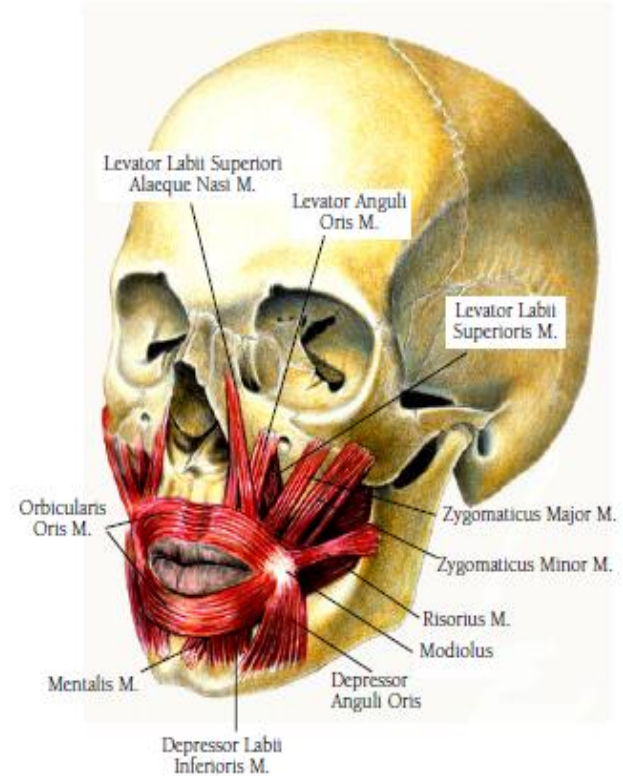


# Orbicularis Oris Muscle

## ORBICULARIS ORIS



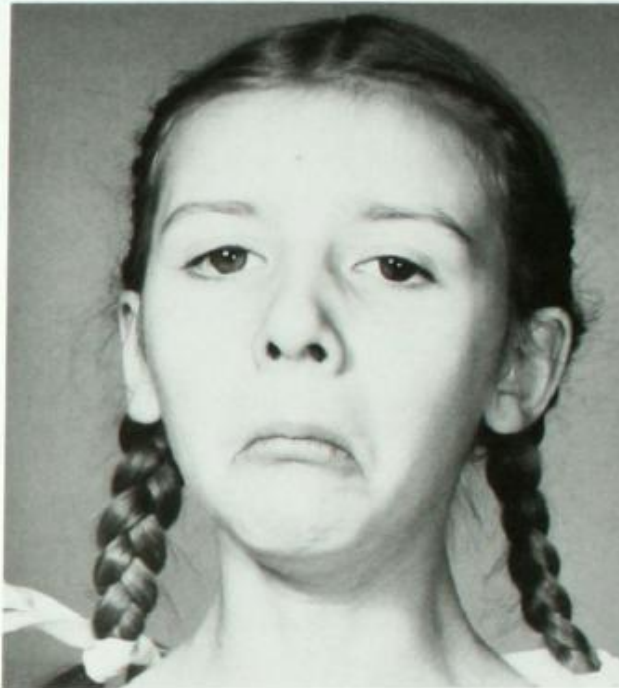Test: Close and protrude the lips, as in whistling.



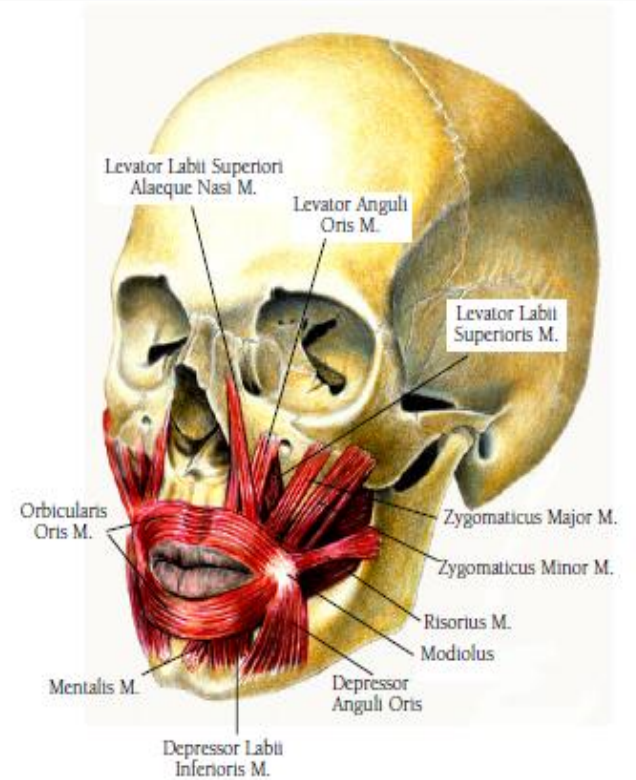
***Test:*** Close and protrude the lips, as in whistling.

# ○ Depressor Anguli Oris Muscle

DEPRESSOR ANGULI ORIS

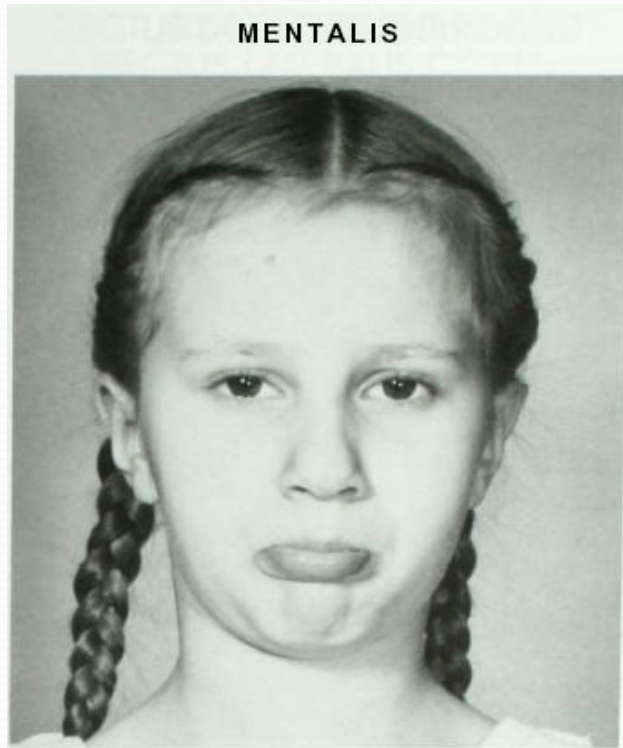

Test: Draw down the angles of the mouth,

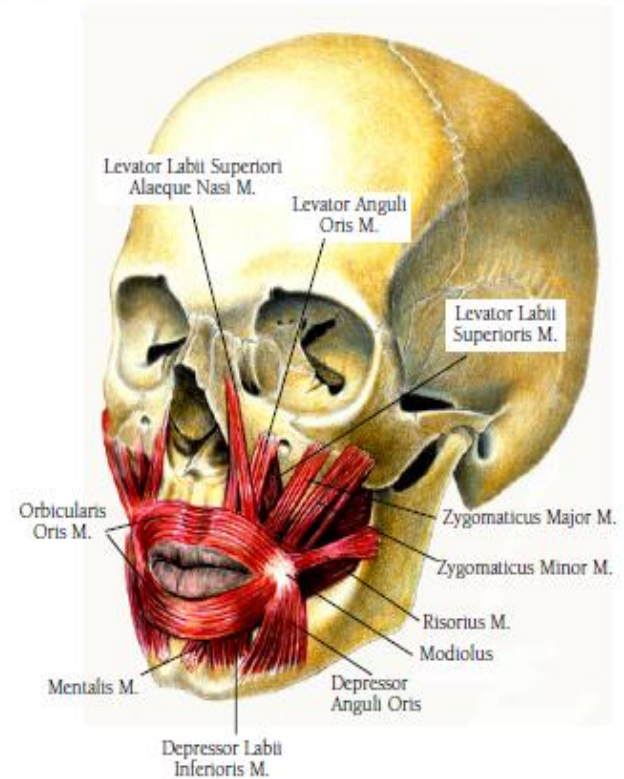


***Test:*** Draw down the angles of the mouth.

# Mentalis Muscle



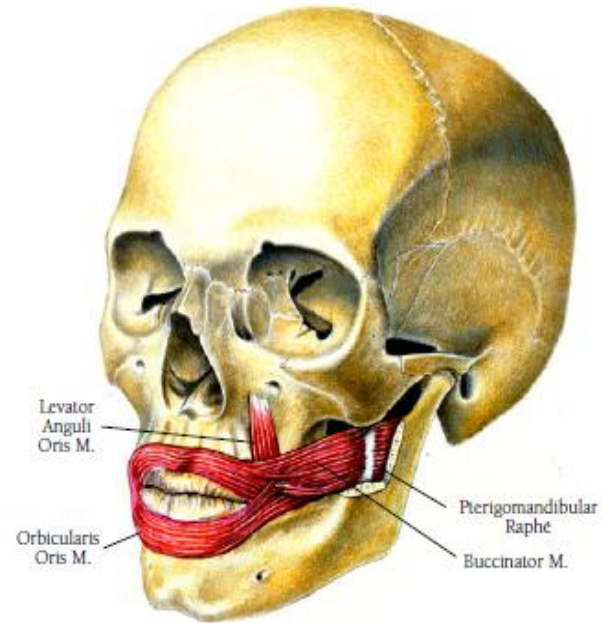
Test: Raise the skin of the chin. As a result, the lower lip will protrude somewhat, as in pouting.



***Test:*** Raise the skin of the chin. As a result, the lower lip will protrude somewhat, as in pouting.

# Buccinator Muscle

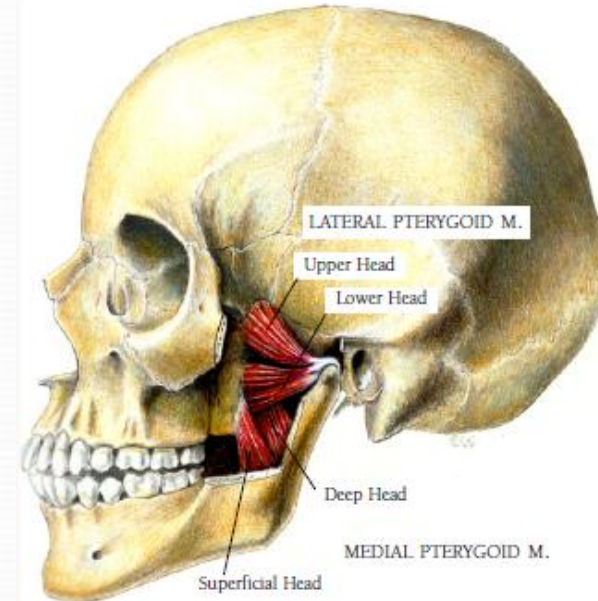
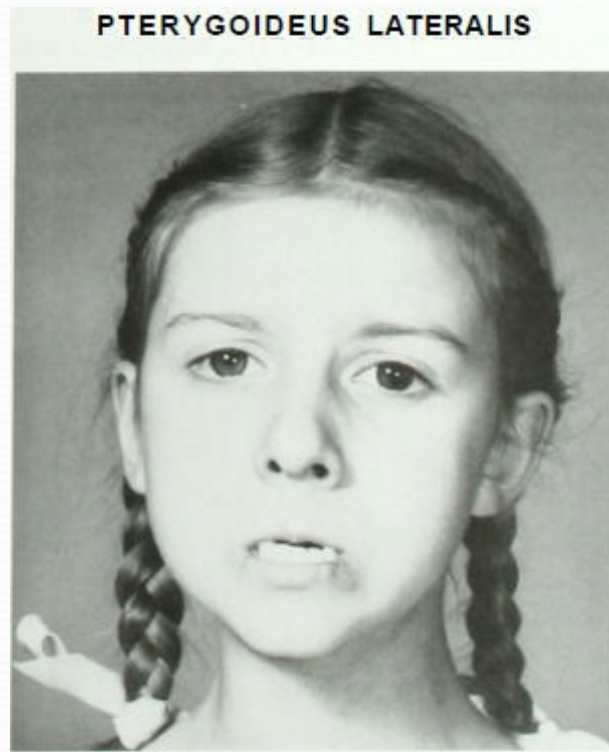BUCCINATOR



**Test:** Press the cheeks firmly against the side teeth and pull back the angle of the mouth, as in blowing a

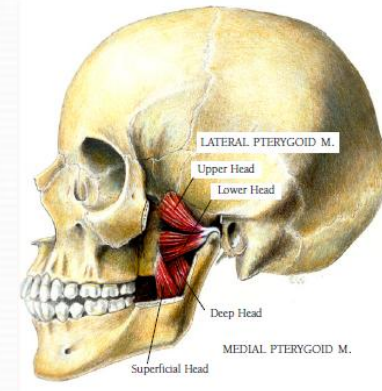
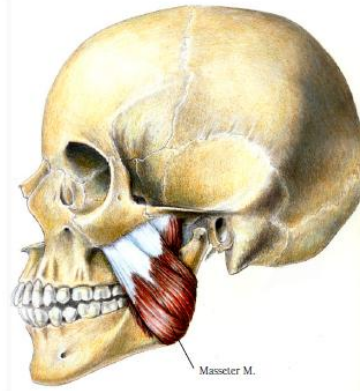
# MUSCLES OF MASTICATION

## ○Pterygoideus Lateralis Muscle




**Test:** Open the mouth slightly. Protrude the lower jaw, and then move the lower jaw sideways, first toward the right and then toward the left

# Temporalis, Masseter, and Pterygoideus Medialis Muscles



***Test:*** Close the jaws, and bite firmly with the mouth slightly open to show that the teeth are being clenched,

# ○Suprahyoid Muscle



**Test:** Depress the lower jaw against resistance provided by the examiner. During action of the suprahyoid muscles, the infrahyoid muscles furnish fixation of the hyoid bone.

***Test:*** Depress the lower jaw against resistance provided by the examiner.